



**PATIENT**

Skizzy Ryan

**SPECIES**

Canine

**BREED**

Miniature Schnauzer

**SEX**

Male Neutered

**AGE**

9.17.15

**WEIGHT**

11.11lbs

**INTERPRETED BY**

Maggie Machen Lamy,  
DVM, DACVIM  
(Cardiology)

**HOSPITAL NAME**

Bel Air Veterinary  
Hospital

**REFERRING VET**

Dr. Schmidt

**INVOICE**

30507

**DATE**

4.28.23

**PRESENTING CLINICAL SIGNS**

History: Presented for lameness. Incidental finding of Cardiomegaly on CXR.

-Current medications: None at this time.

-Sedation used: Not required to complete full diagnostic ultrasound.

-Pertinent previous ultrasound results: No previous.

-STAT: Not requested

-Imaging performed by: Stephanie Warga RDCS, RVT.

**ECHOCARDIOGRAM FINDINGS**

2D, m-mode, color flow and doppler imaging is available. Normal mitral valve leaflets with no prolapse into the left atrial lumen. No obvious mitral regurgitation with a normal left atrial dimension. Normal LV diameter with adequate myocardial function. The tricuspid valve appears normal with no tricuspid regurgitation. Normal right atrial and ventricular diameter and morphology indicating no overt evidence of pulmonary arterial hypertension. The pulmonic and aortic valves are normal in morphology and mobility. Normal pulmonic and aortic outflow velocities with laminar flow. No obvious aortic and mild pulmonic insufficiency. No pericardial or pleural effusion noted. No obvious cardiac masses.

**CARDIAC CHART**

| CANINE CARDIAC PARAMETERS  | MR VMAX (m/s) | TR VMAX (m/s) | LA/AO (Boon method) | LA/AO (Heart Base; Swe) | FS (%)                          | EF (%)                                   | EPSS (cm)                                |
|--|---------------|---------------|---------------------|-------------------------|---------------------------------|--|--|
| NORMAL PARAMETER   | 4.5-5.5       | <2.7          | 1.3                 | <1.6                    | 28-40                           | 40-100                                   | <0.6                                     |
| PATIENT  | NA            | NA            | NM                  | 1.3                     | 33                              | 64                                       | NM                                       |
| CANINE CARDIAC PARAMETERS  | HR (BPM)      | AV VMAX (m/s) | PV MAX (m/s)        | BODY WEIGHT (kg)        | LA 2D short axis Base view (cm) | LVIDd Avg; 2D and m-mode short axis (cm) | LVIDs Avg; 2D and m-mode short axis (cm) |
| NORMAL PARAMETER   | 50-100        | 0.7-1.7       | 0.7-1.6             | BELOW                   | BELOW                           | BELOW                                    | BELOW                                    |
| PATIENT  | 120           | 1.1           | 0.96                | 5.0                     | 1.5                             | 2.5                                      | 1.7                                      |
| *Normal chamber parameters expressed as a mean value (SD)  |               |               |                     | 3                       | 1.27 (5.3)                      | 2.46 (2.46)                              | 1.36 (5.5)                               |
| BODY WEIGHT DEPENDENT PARAMETERS   |               |               |                     | 5                       | 1.40 (4.5)                      | 2.74 (5.2)                               | 1.60 (4.7)                               |
| *Note: All measurements based upon multi-modal images and methods. An average value is reported.<br><br>Adapted from June Boon, Veterinary Echocardiography, 1998<br>Rishniw M and Hollis NE, J Vet Intern Med 2000; 14:429-435<br>Hansson et al, Vet Rad and Ultrasound 2002<br>Bonagura et al. Echocardiography: principles of interpretation, Vet Clin North Am 15:1177, 1995 |               |               |                     | 10                      | 1.50 (3.8)                      | 3.27 (3.5)                               | 2.06 (3.1)                               |
|  |               |               |                     | 15                      | 1.83 (2.0)                      | 3.71 (2.4)                               | 2.43 (2.1)                               |
|  |               |               |                     | 20                      | 2.02 (1.9)                      | 4.14 (2.2)                               | 2.80 (2.0)                               |
|  |               |               |                     | 25                      | 2.18 (2.4)                      | 4.48 (2.9)                               | 3.10 (2.5)                               |
|  |               |               |                     | 30                      | 2.33 (3.3)                      | 4.83 (3.9)                               | 3.39 (3.4)                               |
|  |               |               |                     | 35                      | 2.48 (4.3)                      | 5.17 (5.0)                               | 3.69 (4.5)                               |
|  |               |               |                     | 40                      | 2.62 (5.2)                      | 5.48 (6.1)                               | 3.96 (5.4)                               |
| 50   | 2.88 (7.1)    | 6.07 (8.3)    | 4.46 (7.4)          |                         |                                 |  |  |

## INTERPRETATION OF THE FINDINGS & FURTHER RECOMMENDATIONS

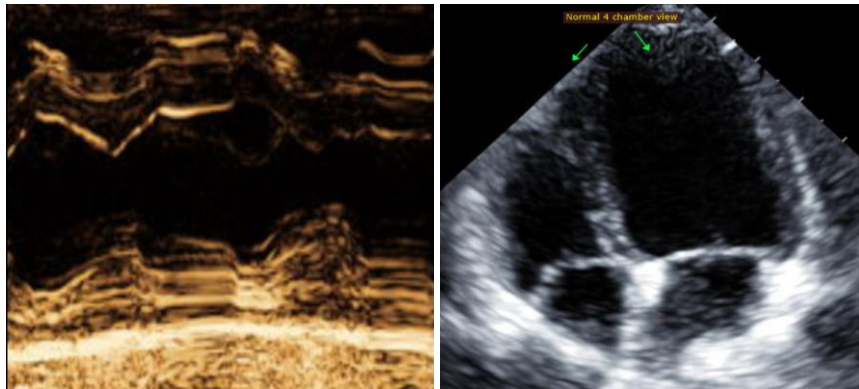
Overtly normal cardiac dimensions and function, with no obvious dysfunction or dilation of the left heart. No significant valvular leaks are visualized, and no evidence of pulmonary hypertension.

These findings would suggest cardiomegaly is a normal variant. These films should be used as a baseline for future comparison.

Monitor for development of a heart murmur, cough, labored breathing, exercise intolerance or collapse episodes.

A recheck echocardiogram is recommended should a significant murmur develop, or signs of cardiac compromise be noted in the future.

## IMAGES



The information and recommendations provided are based on the images presented by the referring veterinarian. No evaluation can be communicated regarding pathology that was not visible in the image/video clips provided.

Thank you for this referral. This report was generated using transcription software, and minor dictation errors may be present. If the clinical or image interpretation does not parallel your findings or if I can be of any further assistance, please contact me.

**Maggie Machen Lamy, DVM**  
Diplomate of the American College of Veterinary Internal Medicine (Cardiology)  
info@sonopath.com